



Effects of Different Types of Honey on Wound Healing in rats

Khaled. M. A. Hussin^{1*}, Asma. Saleh. W. El-Mabrok², Nawara. M. B. Eissa¹, Akaram Husain³ and Marwan Saleh Wanes⁴

¹Department of Medicine and Animal Surgery, Faculty of Veterinary Medicine, Omar Al-Mukhtar University, Al-Bayda, Libya

²Department of Botany, Faculty of Science, Toubrk University, Toubrk, Libya

³Department Food Biotechnology Faculty of Science and Technology, University Sains Lslam Malaysia

⁴Agricultural Research Center, Al-Bayda, Libya

Received: 02 September 2018/ Accepted: 24 October 2018

Doi: <https://doi.org/10.54172/mjsc.v33i3.238>

Abstract: One hundred and twenty healthy female Sprague-Dawley rats weighing between 300 to 350g were used in this study over a 20-day period. They were allocated randomly into 4 groups of 30 animals each. After the creation of 2cm x 2cm open wound, Group I was control treated with Gentamycin ointment. Groups II, III and IV were treated with Different Types of Honey. On application, the honey was well accepted by the animals without any adverse reaction. On clinical examination, Groups II, III and IV showed bright beefy red color granulation tissue with angiogenesis when compared to Groups I. On bacteriological examination, *Staphylococcus aureus*, *Pseudomonas*, *Escherichia coli*, *Proteus* and *Klebsiella species* were isolated from all the groups. Mean percentage of epithelialistion, wound contraction and total healing were significantly better in Group IV (P<0.05). Honey can be a better wound healing biomaterial in rats. It can be used as a less expensive skin substitute in order to stimulate and promote wound healing in animals.

Keywords: Honey, Induced skin wound, wound healing, Rats

INTRODUCTION

A wound is a physical bodily injury resulting in the disruption of normal continuity of structures and wound healing is the restoration of the continuity. The treatment of wounds has improved considerably in the past 30 years, and will continue to progress rapidly with the advancing technology and a greater understanding of chronic wounds (Ashraf. abdel-hamed. Hegazi & Khaled. M. A. Hussin, 2008; Ballard & Baxter, 2000; Khaled. M. A. Hussin & Ashraf. abdel-hamed. Hegazi, 2008; Rafi. Mustafa. Elkaseh. Abdulla, Ashraf. abdel-hamed. Hegaz, & Khaled. M. A. Hussin, 2008). The objectives of any wound management are

relief of pain and distress to the animal, functional and cosmetic repair, economic and time efficient procedures and prompt decision making in the event of signs of delayed healing (Cockbill, 2002). In chronic wounds, the major focus of wound healing has been on the relationship between tissue destruction by excess inflammation and tissue synthesis stimulated by a pro-healing environment. Natural polymers have been increasingly studied for applications in health care due to their biocompatibility, biodegradability, and nontoxicity (Mali, Grossmann, García, Martino, & Zaritzky, 2006). Topical application of honey to wound has been recognized for centuries as effective in controlling infection and producing a clean

*Corresponding Author: Khaled. M. A. Hussin, khaled.elhmri@omu.edu.ly, Department of Medicine and Animal Surgery, Faculty of Veterinary Medicine, Omar Al- Mukhtar University, Al-Bayda, Libya

granulating wound bed. The recorded observations show that inflammation, swelling, and pain are quickly reduced, unpleasant odors cease, sloughing of necrotic tissue occurs without the need for debridement, dressings can be removed painlessly (Dunford, Cooper, Molan, & White, 2000; Peter. C Molan, 1999). It is one of the most enduring materials to be used in wound care, attributed to its antibacterial, anti-inflammatory, and antioxidant properties (Peter. C Molan, 1999) Honey is mildly acidic and has a pH between topical acidification of wounds promotes healing (P. Molan & Betts, 2004; P. C. Molan, 1996; Peter. C Molan, 1999). The hydrogen peroxide produced by honey is responsible for the stimulation of tissue growth. Hydrogen peroxide has been shown to stimulate fibroblast growth in cell culture at micro- and nanomolar concentrations (Schmidt, Chung, Andrews, & Turner, 1992). The medical and nutritional properties of honey depend on its chemical composition. The chemical composition of honey varies depending on the plant source, season, and production methods (Moore et al., 2001). Honey has an obvious potential for use in a variety of clinical settings, and while a few clinics and individuals are using honey therapeutically, further research is needed to determine whether the source of honey can affect wound healing. The present paper discusses the effect of different types of honey for management of an full thickness skin wound in rats.

MATERIALS AND METHODS

Animals: One hundred and twenty healthy female Sprague-Dawley rats weighing between 300 to 350g were used in this study. The animals were randomly into four experimental groups with each group consisted of 30 animals. Group I was left untreated and acts as control group. Group II, III and IV were treated with Hanon honey, Sidr honey and Rosemary honey respectively.

The progress of wound healing was recorded at dyes 4, 8, 12, 16 and Day 20 post-operation.

An Elizabethan collar was applied to prevent self-mutilation of the surgical site.

Honey samples: Three selected honeys which produced by bees from Al-Jabal Al-Akhdar Libya kept under different planting were used in this study the floral sources were Hanon honey from (Arbutus unedo) tree, Sidr honey from (Sidr) tree and Rosemary honey from (Rosemary) tree. The honeys were named according to their floral sources. all the honeys were supplied from Al-Jabal Al-Akhdar farms, Libya.

Surgical protocol: The rats were anaesthetized with an intramuscular injection of 35.0 mg/kg Ketamine and 5.0 mg/kg Xylazine in the gluteal area (Khaled, Asma, & Almahdi, 2016). When fully anaesthetized, the animals were positioned on their dorsal area, which was prepared aseptically for the creation of an open wound (2 X 2cm). The skin was disinfected with hibiscrub, containing 0.6% chlorohexidin then with 70 % alcohol solution and with 2% iodine solution (Druecke et al., 2004).

Using a sterile millimetre ruler and cotton tipped applicator dipped in sterile methylene blue, a 2cm square was drawn on the skin. A full thickness skin defect in which all tissue down to and including the panniculus muscle was excised using no. 15 scalpel blade. Therapeutic ultrasound massage was given on the periwound skin after smearing the area with coupling gel 10mts @ 0.5 watts/ cm² area (Altomare, Nascimento, Romana-Souza, Amadeu, & Monte-Alto-Costa, 2009).

The wound was covered with honey and kept on the wound and protected with a bandage. The limb was immobilized using a PVC splint and bandage. The same procedure was repeated once a week and the progress in healing was evaluated through wound colour coding, nature and quantity of exudates and odour (James & Bayat, 2003).

Clinical observation: The colour of the wound bed gives an indication of the phase of healing. The colour coding taken into account are red, yellow, black and pink areas as the main variables in a wound. Shiny beefy red or red indicates healthy granulation tissue. Yellow colour is due to fibrous tissue or necrotic slough, black is eschar or necrotic tissue and pink or purple means re-epithelialisation has begun (James & Bayat, 2003).

Mal-odour of the wound is commonly associated with infection or attributed to poor hygiene or from a dressing that has not been changed regularly. The presence of necrotic tissue gives off an offensive repulsive odour, and anaerobes typically produce a distinctive or putrid odour (James & Bayat, 2003).

Exudate: Exudates can be scored as no exudates, moderate or excessive. Type of discharge can be described as serous (clear fluid without blood), pus or debris. Serosanguineous and sanguineous indicates thin watery pale red to pink fluid and bloody to bright red, respectively. Purulent discharge is thick, cloudy, and yellow or tans (James & Bayat, 2003).

A more accurate method for determining the wound area in healing studies is tracing of the wound margins onto a clear plastic sandwich film. In this method, a double layer sterile plastic sandwich bag was placed on the wound for tracing; the layer that comes into contact with the wound can be removed and disposed of accordingly. The outer layer was placed on to a graph sheet and the squares were measured by square counting procedure. The number of squares (0.04 cm^2) that lay completely (N_c) and partially (N_p) inside the tracing were counted and the area was determined using the following formula: $A_{c+p} = (N_c + 0.40 \times N_p) \times 0.04$ (Richard, Daures, Richard, Vannereau, & Boulot, 2000). The wound margin at the border between normal skin and the wound and the outlined area was considered to be the total wound area. Next the leading edge of advancing epithelium was traced. The area between

these two margins was considered to be the area for epithelialization. The area within the margin of advancing epithelium was taken as the area of open or unhealed wound (Bohling, Henderson, Swaim, Kincaid, & Wright, 2004).

Calculation of wound healing

Percentage of epithelialization

$$\text{Percentage of epithelialization Day } n = \frac{\text{Area of epithelium Day } n}{\text{Total wound area Day } n} \times 100$$

Percentage of wound contraction

$$\text{Step 1: Total wound on Day } n = \frac{\text{Total wound area Day } n}{\text{Original wound area Day } 0} \times 100$$

Step 2: % wound on Day $n = 100 -$ total wound on Day n as % of original

Percentage of total wound healing was calculated by

$$\text{Step 1: open wound Day } n \text{ as \% of original} = \frac{\text{Open wound area Day } n}{\text{Original wound area Day } 0} \times 100$$

Step 2: Percentage of total wound healing Day $n = 100 -$ open wound Day n as % of original (Bohling et al., 2004; Khaled et al., 2016; Khaled. M. A, Jalila, Kalthum. H, Noordin. M, & Asma. Saleh. W, 2014)

Sterile cotton swabs were rolled over the wounds and streaked on blood and MacConkey agar plates. The colony growth was examined and identified by biochemical test after an incubation period of 24 hours.

Data analysis: In all groups, wound epithelialization, contraction, and total wound healing, analysis across treatment groups were compared using the repeated measures analysis of variance method for Days 0, 4, 8, 12, 16 and 20 post-operation. The significant means were elucidated using Duncan's multiple range tests. All statistical tests were conducted at $P < 0.05$ level of significance.

RESULTS

On application, the Hanon honey, adhered uniformly to the wound site, and were absorbed on

the wound site. No unabsorbed remnants were noticed during the next application. In Groups I and II animals, the wound colour was red up to Day 12 post- operation and pink in colour from Day 16 and 20. Groups III and IV showed bright beefy red colour up to Day 12 and it were red from Day 16 to 20. Malodour was observed up to Day 12 post-operation in Group I and II animals. In Group III and IV mild malodour were observed up to Day 8. Serous exudate was noticed up to Day 12 in Group I. Mild serous exudate was noticed up to Day 8 post-operation in Group II animals. No exudate was seen in Groups III and IV animals throughout the study (Table 1).

Table:(1). Clinical observation of the open wound

	Days	Group I	Group II	Group III	Group IV
Colour	4	Red	Red	Red	Bright shiny red
	8	Red	Red	Bright shiny red	Bright shiny red
	12	Red	Red	Bright shiny red	Bright shiny red
	16	Pink	Pink	Red	Red
	20	Pink	Pink	Pink	Pink
Odour	4	Malodour	Malodour	Mild malodour	Mild malodour
	8	Malodour	Malodour	Mild malodour	Mild malodour
	12	Malodour	Malodour	No odour	No odour
	16	No odour	No odour	No odour	No odour
	20	No odour	No odour	No odour	No odour
Exudate	4	Exudate	Mild exudates	No exudates	No exudate
	8	Exudate	Mild exudates	No exudates	No exudate
	12	Exudate	No exudates	No exudates	No exudate
	16	No exudate	No exudates	No exudates	No exudate
	20	No exudate	No exudates	No exudates	No exudate

The percentage of epithelialization was consistently better in Group IV throughout the trial. The difference between Groups I, II, and III compared to IV were evident as early as Day 4. The percentage of epithelialization improved from 18.68% (Day 4) to almost 99.41% on Day 20 in Group IV. This was almost twice that of Group I until Day 12. Groups II and III however, demonstrated more than average epithelialization throughout the trial (Figure 1). The percentage of wound contraction was better in Group III up to Day 12 (59.24%), however, it was best in Group IV on Days 16 and 20. The difference between Groups II, III and IV compared to Group I was evident on Day 8. The percentage of wound contraction improved from 75.64 % (Day 16) to almost 93.13 % on Day 20 in Group IV, but Group III showed an improvement from 17.69 % (Day 4) to almost

84.55 % on Day 20, and Group II showed an improvement from 15.68 % (Day 4) to almost 78.57 % on Day 20. Nevertheless, Group IV demonstrated better than average total wound healing throughout the trial (Figure 2).

The percentage of wound contraction was better in Group IV throughout the trial. The difference between the animals in Groups II, III and IV compared to Group I was evident from Day 8. The percentage of total wound healing improved from 38.59 % (Day 4) to almost 99.13 % on Day 20 in Group IV. However, Group IV, demonstrated better than average total wound healing throughout the study (Figure 3).

On bacteriological examination, *Staphylococcus aureus*, *Pseudomonas*, *Escherichia coli*, *Proteus* and *Klebsiella species* were isolated from all the Groups.

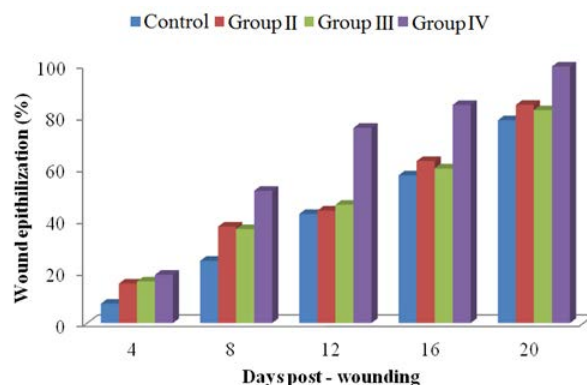


Figure: (1). Percentage of epithelialization of the wound

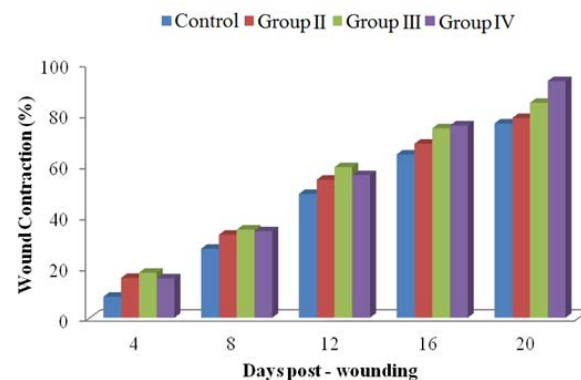


Figure: (2). Percentage of contraction of the wound

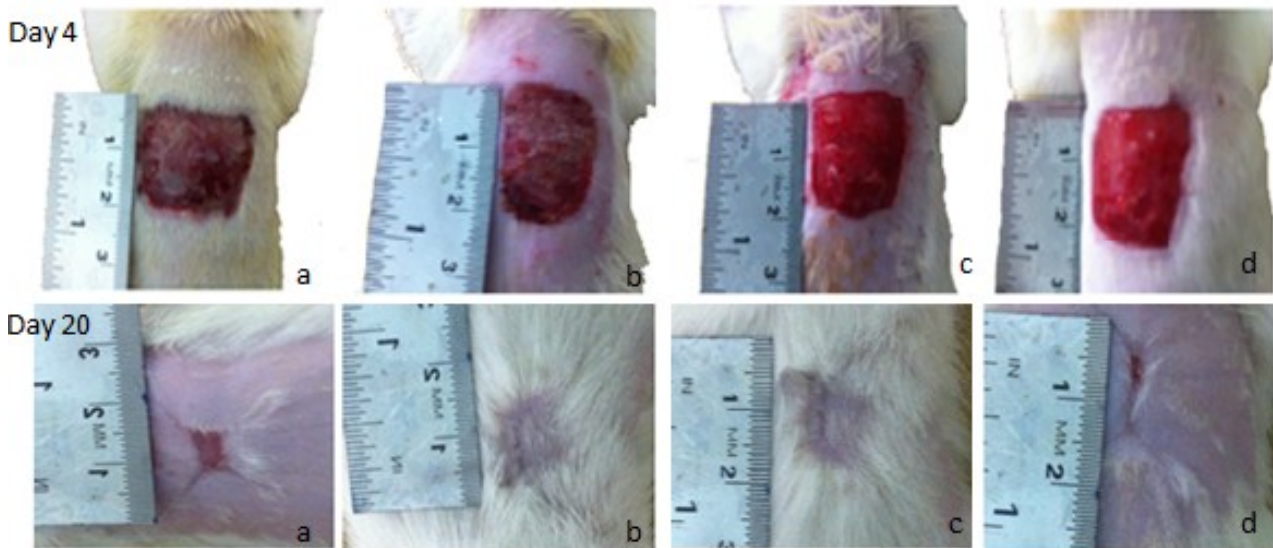


Figure (3): Percentage of total wound healing of the wound, Open wound on day 4 and 20 post-wounding: a) Group I; b) Group II; c) Group III; Group IV

DISCUSSION

In Groups II, III and IV, the application of honey was well tolerated by the animals. The honey is easy to apply on the wound without any adverse reaction and was well accepted by all the animals. The application of Hanon honey did not show any adhesion of the gauze during wound dressing.

The colour of the wound bed in Groups I and II was red while Groups III and IV showed a bright beefy red colour, which indicates healthy granulation tissue with neovascularisation, (James and Bayat, 2003) and resistance to infection until the epithelial barrier is re-established (Hosgood, 2003; Pope, 1993). The bright red colour observed is due to the micro vascular network throughout the granulation tissue (Tonnesen, Feng, & Clark, 2000). The basic fibroblast growth factor set the stage for angiogenesis during the first three days of wound repair (Schäffer, Tantry, & Barbul, 2004) and plays an important role in granulation tissue formation and the wound healing process (Takehara, 2000). Granulation in all the cases was flat without any exuberant nature; granulation tissue with a smooth surface facilitates migration of epithelial cells (Pope,

1993). On Days 16 and 20, the granulation tissue was observed to be pink in colour in Groups I and II, which indicates the final stage of wound healing. In Groups III and IV the granulation tissue was red in colour due to neovascularisation (James & Bayat, 2003).

Mal-odour was observed up to Day 12 in Groups I and II; however, in Groups III and IV mild mal-odour was observed up to Day 8 which may be due to infection (James & Bayat, 2003). The presence of bacterial infection was the common cause for the mal-odour observed, because all the wounds were infected. Serous discharge was noticed up to Day 12 in Group I and mild serous discharge was noticed up to Day 8 in Groups II and III; subsequently, the discharge was reduced because healthy vascular granulation tissue is resistant to infection (Hosgood, 2003; Pope, 1993).

Wound epithelialisation of Group IV was consistently better than Group I, and also better than Groups II and III because the re-epithelialisation process in a full-thickness wound is accelerated by the presence of collagen and its proliferation is essential for optimal wound healing (Rangaraj, Harding, & Leaper, 2011). On Day 4, epithelialisation was signifi-

cantly better in Groups II, III and IV, compared to Group I, because collagen from the wound margins began to migrate to form new epithelium (Rangaraj et al., 2011).

The mean percentage of wound epithelialisation in Group IV was maximum between Days 4 and 8 (32.56 %) but in Groups I, II and III, it was between Days 16 and 20 (21.36%, 21.79% and 22.61 %). Collagen is a potent specific growth factor for epithelial cells and assists in re-epithelialisation (Rangaraj et al., 2011).

The percentage of wound contraction on post wound Days 4 and 8 of all Groups showed no significant difference, this may be because of an inherent property of fibroblasts that appears early in the process of wound contraction, which, after some time, do not contract as forcefully as those that appear later (Bohling et al., 2004). Schaffer et al. (2004) reported that there is increased fibroblast activity of the body until post-wound Day 14. On Days 12, 16 and 20, Group IV was significantly better than Groups I, II and III since basic fibroblast growth factor effectively accelerated wound fibroblast proliferation (Kawai, Suzuki, Tabata, Ikada, & Nishimura, 2000) and has a characteristic myofibroblastic appearance, which plays a critical role in closure and healing (Cheng et al., 1999).

The mean percentage of wound contraction of Group IV on Day 20 was significantly better than other groups; in open wounds, contraction becomes an important feature and epithelialisation assumes a more predominant role. However, the two processes are independent of each other (Probst, 2003). All the groups showed maximum rates of contraction in the period between Days 8 and 12 post-wound; similar findings have been previously reported (Aljady, Kamaruddin, Jamal, & Mohd-Yassim, 2000; Baie & Sheikh, 2000; Bohling et al., 2004; Swaim et al., 1993).

The percentage of total wound healing of Group IV was significantly better than Group I

and consistently better than Group II and III because of more rapid epithelialisation; there is a corresponding reduction in area of exposed granulation tissue in the wound (Bohling et al., 2004). On Day 20, among Groups II, III and IV there was no significant difference but healing was significantly better than in Group I. Basic FGF is well known for promoting the proliferation of almost all cells associated with wound healing (Michiyo, Toshito, & Shigehiko, 2005). All the groups showed maximum mean percentage of total wound healing from Days 4 to 8; this is in concurrence with the results of Bohling, *et al.* (2004) but differs from the findings of Swaim, *et al.* (1993). *Staphylococcus aureus*, *Pseudomonas*, *Klebsiella sp* *Escherichia coli* is the common infection in wounds (Kumar, Sripriya, Raghavan, & Sehgal, 2006). All wounds can be contaminated regardless of the precautions taken (Arul Jothi et al., 2006).

It is a biocompatible protein that does not interfere with the body's normal immunologic response and can be used in non-healing chronic wounds, which require a trigger to stimulate the normal healing process.

CONCLUSION

Honey can be a better wound healing biomaterial in rats. It can be used as a less expensive skin substitute in order to stimulate and promote wound healing in animals.

ACKNOWLEDGEMENT

The authors would like to thank the Dean of the Faculty of Veterinary Medical, the Head of Department of Medicine and Animal Surgery for the facilities provided and help rendered during the study.

REFERENCES

Aljady, A., Kamaruddin, M., Jamal, A., & Mohd-Yassim, M. (2000). Biochemical study on the efficacy of Malaysian honey on inflicted wounds: an animal

- model. *Medical Journal of Islamic Academy of Sciences*, 13(3), 125-132.
- Altomare, M., Nascimento, A. P., Romana-Souza, B., Amadeu, T. P., & Monte-Alto-Costa, A. (2009). Ultrasound accelerates healing of normal wounds but not of ischemic ones. *Wound repair and regeneration*, 17(6), 825-831.
- Arul Jothi, N., Thilagar, S., Khaled, M. A., Thevi, S. G., Lau, S., & Sastry, T. (2006). Clinical evaluation of keratin-gelatin composite film for wound healing in cats. *Indian Journal of Veterinary Surgery*, 27(2), 108-110.
- Ashraf. abdel-hamed. Hegazi, & Khaled. M. A. Hussin. (2008). Diagnosis of joint affection in camels by studies on synovial fluid which give the degree of affections & response to treatment. *Al-Mukhtar Journal of Sciences*, 20(1), 58-76.
- Baie, S. H., & Sheikh, K. A. (2000). The wound healing properties of *Channa striatus*-cetrimide cream—tensile strength measurement. *Journal of ethnopharmacology*, 73(1), 15-30.
- Ballard, K., & Baxter, H. (2000). Developments in wound care for difficult to manage wounds. *British journal of Nursing*, 9(7), 405-412.
- Bhatia, P., & Ashwath, N. (2002). *Development of a rapid method for micropropagation of a new pineapple [Ananas comosus (L.) Murr.] clone, 'Yeppoon gold'*. Paper presented at the International Symposium on Tropical and Subtropical Fruits 575.
- Bohling, M. W., Henderson, R. A., Swaim, S. F., Kincaid, S. A., & Wright, J. C. (2004). Cutaneous wound healing in the cat: a macroscopic description and comparison with cutaneous wound healing in the dog. *Veterinary Surgery*, 33(6), 579-587.
- Cheng, B., Fu, X., Sheng, Z., Gu, X., Sun, T., & Sun, X. (1999). The effect of basic fibroblast growth factor on myofibroblasts and its significance on wound healing. *Zhonghua yi xue za zhi*, 82(17), 1187-1191.
- Cockbill, S. (2002). Wounds the healing process. *Hospital pharmacist-london*, 9(9), 255-260.
- Consultation, W. (1999). Definition, diagnosis and classification of diabetes mellitus and its complications: Part.
- Druecke, D., Lamme, E. N., Hermann, S., Pieper, J., May, P. S., Steinau, H. U., & Steintraesser, L. (2004). Modulation of scar tissue formation using different dermal regeneration templates in the treatment of experimental full-thickness wounds. *Wound repair and regeneration*, 12(5), 518-527.
- Dunford, C., Cooper, R., Molan, P., & White, R. (2000). The use of honey in wound management. *Nursing Standard (through 2013)*, 15(11), 63.
- Hamad, A. M., & Taha, R. M. (2008). Effect of sequential subcultures on in vitro proliferation capacity and shoot formations pattern of pineapple (*Ananas comosus* L. Merr.) over different incubation periods. *Scientia Horticulturae*, 117(4), 329-334.
- Hosgood, G. (2003). Wound repair and specific tissue response to injury. *Textbook of Small Animal Surgery. 3rd ed. Philadelphia: WB Saunders, 1*, 327-329.

- James, A., & Bayat, A. (2003). basic plastic surgery techniques and principles: chronic wound management. *Student Br Med J*, 11, 406-407.
- Kawai, K., Suzuki, S., Tabata, Y., Ikada, Y., & Nishimura, Y. (2000). Accelerated tissue regeneration through incorporation of basic fibroblast growth factor-impregnated gelatin microspheres into artificial dermis. *Biomaterials*, 21(5), 489-499.
- Khaled, M. A. H., Asma, S. E., & Almahdi, A. K. H. (2016). Clinical Evaluation of Collagen-Calcium Alginate Film along with Therapeutic Ultrasound Massage for Wound Healing in Cats. *Acta Biologica Malaysiana*, 5(2&3), 49-52.
- Khaled. M. A. Hussin, & Ashraf. abdelhamed. Hegazi. (2008). Unusual foreign bodies causes obstruction of the esophagus in dogs. *AL-Mukhtar Journal of Sciences*, 19(1), 51-61.
- Khaled. M. A, Jalila, A., Kalthum. H, Noordin. M, & Asma. Saleh. W. (2014). Collagen-Calcium Alginate Film Dressing with Therapeutic Ultrasound to Treat Open Wound in Rats. *Research Journal of Biological Sciences*, 9(2), 57-61.
- Kumar, M. S., Sripriya, R., Raghavan, H. V., & Sehgal, P. V. (2006). Wound Healing Potential of *Cassia fistula* on Infected Albino Rat Model. *Journal of Surgical Research*, 131(2), 283-289.
- Mali, S., Grossmann, M. V. E., García, M. A., Martino, M. N., & Zaritzky, N. E. (2006). Effects of controlled storage on thermal, mechanical and barrier properties of plasticized films from different starch sources. *Journal of food engineering*, 75(4), 453-460.
- Michiyo, M., Toshito, I., & Shigehiko, S. (2005). Effrcts of bFGFgelatin composite film incorporated into gelatin sheet on wound healing. *J. Biomat. sci. poly. ed*, 16(7), 893-907.
- Molan, P., & Betts, J. (2004). Clinical usage of honey as a wound dressing: an update. *Journal of wound care*, 13(9), 353-356.
- Molan, P. C. (1996). Honey as an antimicrobial agent. *Bee Products*, 3, 27-37.
- Molan, P. C. (1999). The role of honey in the management of wounds. *Journal of wound care*, 8(8), 415-418.
- Moore, O. A., Smith, L. A., Campbell, F., Seers, K., McQuay, H. J., & Moore, R. A. (2001). Systematic review of the use of honey as a wound dressing. *BMC complementary and alternative medicine*, 1(1), 2.
- Pope, E. R. (1993). skin healing .In: Disease mechanisms in small animal surgery. *2nd ED Philadelphia, London*, 152-155.
- Probst, C. W. (2003). Wound healing and specific tissue regeneration. In. *Texbook of small animal surgery. 3rd Ed. Saunders Company. Philadelphia, I*, 53-63.
- Rafi. Mustafa. Elkaseh. Abdulla, Ashraf. abdelhamed. Hegaz, & Khaled. M. A. Hussin. (2008). Foreign Bodies in the rumen of the Sheep and Goats. *Al-Mukhtar Journa of Sciences*, 19(1), 38-50.
- Rangaraj, A., Harding, K., & Leaper, D. (2011). Role of collagen in wound management. *Wounds UK*, 7(2), 54-63.
- Richard, J. L., Dures, J. P., Richard, C. P., Vannereau, D., & Boulot, I. (2000). Of

mice and wound reproducibility and accuracy of a novel planimetry program for measuring wound area. *Wounds*, 12(6), 148-154.

Schäffer, M. R., Tantry, U., & Barbul, A. (2004). Wound fluid inhibits wound fibroblast nitric oxide synthesis. *Journal of Surgical Research*, 122(1), 43-48.

Schmidt, R., Chung, L., Andrews, A., & Turner, T. (1992). *Hydrogen peroxide is a murine (L929) fibroblast cell proliferant at micro-to nanomolar concentrations*. Paper presented at the Second European Conference on Advances in Wound Management, Harrogate, October 20-23.

Swaim, S., Bradley, D., Spano, J., McGuire, J., Hoffman, C., & Trachy, R. (1993). Evaluation of multipeptide-copper complex medications on open wound healing in dogs. *The Journal of the American Animal Hospital Association*, 29, 519-525.

Takehara, K. (2000). Growth regulation of skin fibroblasts. *Journal of dermatological science*, 24(1), 70-77.

Tonnesen, M. G., Feng, X., & Clark, R. A. F. (2000). Angiogenesis in wound healing. *Journal of Investigative Dermatology Symposium Proceedings*, 5(1), 40-46.

تأثير أنواع مختلفة من العسل على التئام الجروح في الجرذان

خالد مسعود عبدالخالق^{1*}، أسماء صالح ونيس²، نواره محمد بالقاسم¹ أكرم حسين³ ومروان صالح ونيس⁴

¹ قسم طب وجراحة الحيوان، كلية الطب البيطري، جامعة عمر المختار، البيضاء، ليبيا، ² قسم النبات، كلية العلوم، جامعة طبرق، طبرق، ليبيا، ³ قسم الاغذية الحيوية، كلية العلوم والتكنولوجيا، جامعة العلوم الاسلامية الماليزية، ماليزيا، ⁴ مركز البحوث الزراعية والحيوانية، البيضاء، ليبيا

تاريخ الاستلام: 02 سبتمبر 2018 / تاريخ القبول: 24 أكتوبر 2018

<https://doi.org/10.54172/mjsc.v33i3.238>:Doi

المستخلص: الجرح هو إصابة جسدية تؤدي إلى تعطيل الاستمرارية الطبيعية للبناء، وشفاء الجروح هو استعادة الاستمرارية. تحسنت معالجة الجروح بشكل كبير في الثلاثين سنة الماضية، وسوف تستمر في التقدم بسرعة مع التكنولوجيا المتقدمة وفهم أكبر للجروح المزمنة، في هذه الدراسة تم استخدام مائة وعشرون من إناث الجرذان التي يتراوح وزنها بين 300 إلى 350 جرام على مدى 20 يومًا. تم توزيعها عشوائيًا إلى 4 مجموعات في كل مجموعة 30 حيوان. بعد إنشاء جروح مفتوحة 2 سم × 2 سم، تم علاج المجموعة الأولى بمرهم جنتاميسين والمجموعات الثانية والثالثة والرابعة تمت معاملتها بأنواع مختلفة من العسل، حيث أعطت نتائج جيدة علي الحيوانات دون أي رد فعل سلبي في الفحص السريري، أما المجموعتان الثالثة والرابعة فقد كونت نسيج حبيبي مع تكوين أوعية دموية بالمقارنة مع المجموعتين الأولى والثانية، وعند الفحص البكتيري، تم عزل الأنواع البكتيرية التالية *Staphylococcus aureus*، *Pseudomonas*، *Escherichia coli*، *Proteus* و *Klebsiella* في جميع المجموعات، بينما كان انكماش الجروح والشفاء الكلي أفضل بكثير في المجموعة الرابعة بعد معاملتها بعسل الحنون، ومن المعروف إن العسل هو بروتين حيوي لا يتعارض مع الاستجابة المناعية الطبيعية للجسم ويمكن استخدامه في الجروح المزمنة الغير شافية، والتي تتطلب التحفيز لعملية الشفاء الطبيعية، في الجروح الواسعة عندما يكون هناك نقص في الأنسجة الذاتية.

الكلمات المفتاحية: العسل، تقلص الجروح، التئام الجروح، الجرذان.