



Purple Urine Bag Syndrome: Uncommon Clinical Entity Associated with Common Infection, Case Report

Muftah H. Elkhafifi

Division of urology, surgical specialties center, Benghazi, Libya

Received: 21 September 2020/ Accepted: 18 December 2020

Doi: <https://doi.org/10.54172/mjsc.v35i3.250>

Abstract: Purple urine bag syndrome (PUBS) is a rare medical syndrome where purple discoloration of urine occurs predominantly in chronically constipated bedridden elderly women, chronically catheterized and associated with urinary tract infections (UTIs). The etiology is related to UTIs with specific bacteria that produce sulphatase and phosphatase enzymes which lead tryptophan metabolism to produce two pigments: Indigo (blue) and indirubin (red), mixtures of which become purple in color. Several risk factors are associated with PUBS; including female gender, increased dietary tryptophan, alkaline urine, constipation, catheterization, high urinary bacterial load, renal failure and use of polyvinyl chloride plastic catheters. Herein, I present this rare benign interesting condition on a 78 years old lady with purple discoloration of her urine bag due to urinary tract infection caused by *Escherichia coli* that was successfully treated by culture guided antibiotic (Ciprofloxacin). The purple urine disappeared after antibiotic therapy and change of the urine catheter and bag.

Keywords: Urinary tract infections, catheterization, alkaline urine, tryptophan, purple discoloration, Benghazi.

INTRODUCTION

Purple urine bag syndrome (PUBS) is an uncommon phenomenon reported mostly in chronically constipated, institutionalized females on an indwelling catheter. (Gandhi, 2013) It is a rare complication of UTIs in which patients produce purple urine in their catheter tubing and bags. (Kalsi et al., 2017) Although it is an essentially benign condition, yet the purplish discoloration may be distressing for the patients and their families as well as for healthcare providers (Yaqub et al., 2013) The bluish discoloration is proposed to be due to the breakdown of tryptophan metabolites by bacteria. This usually occurs in alkaline urine although a case of PUBS in acidic urine has also been reported. (Chung et al., 2008). The rarity of this interesting clinical entity necessitates its presentation as the recognition of it is important as treatment is simple and can mini-

mize patients and family distress as well as over management. To the best of our knowledge, this the first case of PUBS reported in our department.

CASE PRESENTATION

A 78-year- Egyptian blind female, who is a known case of hypertension on regular treatment with ACE inhibitor and type II diabetes mellitus on insulin therapy. She had history of left above knee amputation and amputation of right 4th and 5th toes 2 years and 5 years ago respectively. She is bed ridden, chronically constipated and had an indwelling urethral catheter in situ for the last two years which is used to be regularly changed every three weeks, brought by her family to our outpatient department (OPD) with complaints of anorexia, fatigability, constipation and purple discoloration of her urine bag (figure 1) for the past 3-4 days. There was no medi-

*Corresponding Author: Muftah H. Elkhafifi abdokha2007@gmail.com Division of urology, surgical specialties center, Benghazi, Libya.

cation prescribed to her that could have caused this discoloration. On general physical examination, the patient was conscious, oriented and not in pain but there was a striking pallor (+++) and mild dehydration. Her vital signs are as follows; blood pressure 145/70 mmHg , pulse rate 79 bpm, temperature 37 C° and respiratory rate was 16 bpm. Systemic examination revealed a hemic murmur and normal heart sounds, mild decrease of air entry on left side. Her abdomen was soft, lax with no tenderness or organomegally and normally audible bowel sounds. Her baseline investigations showed Hemoglobin 7.8g/l, WBC 5.8*10⁶/L and platelets count was 167*10⁹/ L. Blood glucose level was 288mg/dl and HbA1c was 12.55%. Renal function profile was within normal limits; where blood urea was 26mg/ and serum creatinine 0.9mg/dl. Liver function tests were within normal limits except her serum albumin which was marginal (3.5 gm./dl). Routine urine analysis showed an alkaline PH (PH 8), 3 +++ albuminuria, 1+ blood, while negative for nitrates and bilirubin. Urine microscopy revealed 3-5HPF leukocytes, 2-4 HPF red blood cells and 3+++ triple phosphate crystals. Urine culture grew a heavy growth of *Escherichia coli* sensitive to ciprofloxacin. The patient was managed as an OPD case by changing the urethral Catheter and urine bags along with prescribing her a culture guided antibiotic (Ciprofloxacin) 500 mg twice daily for ten days along with laxative. She scheduled for follow-up after one week and referred to her attending physician for control of her blood sugar and correction of Co-existing anemia. The patient was seen after 7 days, and reported resolution of symptoms and almost disappearance of purple color (figure 2). There was no recurrence of discoloration of her urine during her short follow-up visits. Six weeks later, her urine culture grew growth of *Enterobacter* spp. which is sensitive to Gentamycin but there was no purple discoloration of urine or tubing.



Figure: (1). Purple discoloration of urine bag at presentation



Figure :(2). Urine bag of the same patient after completion of one week of antibiotic therapy.

DISCUSSION

Purple urine bag syndrome (PUBS) is a rare medical phenomenon, and despite being benign, is a cause of distress for the treating physician and patients. (Yadav et al., 2016) This syndrome is commonly reported in elderly (commonly females) having constipation / gastroparesis and alkaline urine , along with chronic indwelling urinary catheter (Fu-Hsiung Su et al., 2005; Rawal et al., 2015). Surprisingly, PUBS has been known for a long time. King George III had blue urine during a bout of chronic constipation. (Kalsi et al., 2017) PUBS , First reported in 1978 by Barlow and Dickson, it has been transcendently observed in bed-bound elderly women who require long-term urinary bladder catheterization(Khalid et al., 2016) Even though the occurrence of urinary tract infection is commonly encountered in every day practice, the presence of a purple bag is a rare clinical entity (Pillai et al., 2009) The prevalence rate of PUBS in literature ranges from 8-16% in different studies (Shiao et al., 2008). Most of the published literature on PUBS is based on case reports, with only a few retrospective/cross sectional studies (Yaqub et al., 2013).

A search of PubMed articles published between 1980 October and 2016 August was conducted, in which 106 articles (174 cases) described.(Yang & Su, 2018). PUBS is usually a side effect of prolonged catheterization (per-urethral or Suprapubic) along with UTI. Other risk factors for PUBS include alkaline urine, female gender , constipation and chronic renal failure. (Khan et al., 2011) (Table 1).

The pathophysiology of PUBS is related to the sequential chemical reactions involving tryptophan metabolism from the food in the gut. Tryptophan is an essential amino acid where it is metabolized(deaminated) by intestinal bacteria to indole , which is absorbed

into the portal circulation and undergoes conjugation in the liver and is subsequently converted into indoxyl sulphate(Indican) . Indican is excreted in the urine and converted into indoxyl by the enzymes: phosphatase or sulphatase produced by Gram – negative Bacteria. This indoxyl is oxidized in alkaline urine to produce two pigments; indigo (blue) and indirubin (red), which in reaction with the plastic (polyvinyl chloride) of the urine bag, result in the purple discoloration. (Figure 2) (Hadano et al., 2012; Yadav et al., 2016).

Interestingly, when the urine is put in contact with other sterile urine containers, no color changes take place. The longer the urine is left in contact with the catheter plastic, the deeper the purple color produced.(Al-Sardar & Haroon, 2009). The commonest implicated organisms include *Providencia* spp., *Klebsiella pneumoniae*, *E.coli*, *Proteus* spp., *Morganella* spp., *Pseudomonas* spp. and *Enterobacter* species. It is occasionally difficult to differentiate which organisms are responsible, as the isolation of multiple organisms is not uncommon(Gandhi, 2013) It is important to note that not all bacteria can cause PUBS, even among the same species, and this is why PUBS is so rare (Khan et al., 2011). The association of PUBS with constipation has long been documented (Dealler et al., 1988; Lin et al., 2002). Increased transit time during constipation allows more time for deamination. However, this alone is not the sole contributory factor as discoloration has also been reported in association with diarrhea.(Al Montasir & Al Mustaque, 2013; Khalid et al., 2016). The management of PUBS should include treating the UTI (e.g., with Ciprofloxacin) and any constipation as well as sanitation measures including replacing the catheter. Another approach is to use intravenous antibiotics if the PUBS persists or the patient is in an immunocompromised state.(Agapakis et al., 2014). It is important to change drainage bags and indwelling long-term catheters

on a regular basis to prevent recurrence and because persistent PUBS can lead to Fournier’s gangrene which requires surgical debridement.(Khan et al., 2011). In addition to the above mentioned steps regarding the management of PUBS, here are some preventive measures:

- Avoid UTI by drinking at least 2000 - 3000 ml of fluids, but avoid beverages with sugar, caffeine and alcohol .As these drinks may increase bladder irritation and contribute to UTI.
- Sometimes vitamin C is recommended to make urine more acidic which can help to prevent or treat UTI.
- Maintain regular bowel program by:
 - Eating high fiber diet
 Establish regular exercise program if applicable
- It is not recommended in the literature that dietary restriction of tryptophan is needed to reduce the incidence of PUBS in patients with long –term indwelling urine catheters

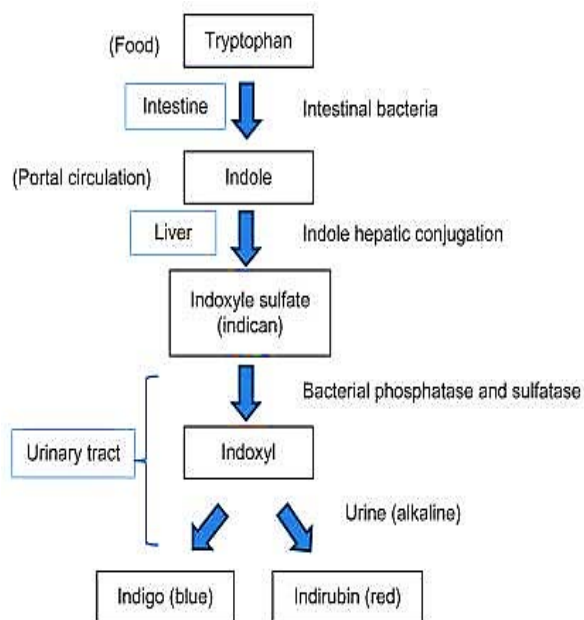


Figure: (2). Pathway of pathogenesis of Purple Urine Bag syndrome (Khan et al., 2011)

Table: (1). Risk factors and possible mechanism involved in pathogenesis of PUBS (Yang & Su, 2018)

Risk Factor	Mechanism
Female gender	Anatomy predispose to UTIs
Increased dietary tryptophan	Increased substrate for conversion
Increased urine alkalinity	Facilitate indoxyl conversion
Sever constipation	Increased time and substrate for bacteria
Chronic catheterization	Increased UTI risk
High urinary bacterial load	Bacterial sulphatase/phosphatase availability
Renal failure	Impaired indoxyl sulphatase clearance

CONCLUSION

Although PUBS is a benign clinical entity, it is alarming and distressing to patients and their families. It is nothing but it serves as an indicator of UTI in patients with various comorbidities as they may not manifest the classical signs of UTI. It is important that the attending physician needs to be familiar with its pathogenesis and simple management; so that expensive and irrelevant investigations can be avoided and the treatment with antibiotics can be started early on the basis of suspicion.

ACKNOWLEDGMENTS.

The author gratefully acknowledges his patient and her family members for permission of publication of her case.

Conflict of interest

There are no conflicts of interest regarding the publication of this paper.

Patient's consent. An informed written consent was obtained from patient's family members regarding the publication of her case

REFERENCES

Agapakis, D., Massa, E., Hantzis, I., Paschoni, E., & Satsoglou, E. (2014). Purple urine

- bag syndrome: a case report of an alarming phenomenon. *Hippokratia*, 18(1), 92.
- Al-Sardar, H., & Haroon, D. (2009). Purple urinary bag syndrome. *The American Journal of Medicine*, 122(10), e1-e2.
- Al Montasir, A., & Al Mustaque, A. (2013). Purple urine bag syndrome. *Journal of Family Medicine and Primary Care*, 2(1), 104.
- Chung, S.-D., Liao, C.-H., & Sun, H.-D. (2008). Purple urine bag syndrome with acidic urine. *International Journal of Infectious Diseases*, 12(5), 526-527.
- Dealler, S. F., Hawkey, P. M., & Millar, M. R. (1988). Enzymatic degradation of urinary indoxyl sulfate by *Providencia stuartii* and *Klebsiella pneumoniae* causes the purple urine bag syndrome. *Journal of Clinical Microbiology*, 26(10), 2152-2156.
- Fu-Hsiung Su, B., Shin-Yi Chung, R., Mey-Huy Chen, R., Mei-Ling Sheng, R., Ching-Hao Chen, R., Ya-Jung Chen, R., Wen-Cheng Chang, R., Lan-Ying Wang, R., & Kai-Yang Sung, M. (2005). Case analysis of purple urine-bag syndrome at a long-term care service in a community hospital. *Chang Gung Med J*, 28(9), 636-642.
- Gandhi, K. (2013). Purple urine bag syndrome: A case report. *Internet Journal of Medical Update-EJOURNAL*, 8(2), 65-66.
- Hadano, Y., Shimizu, T., Takada, S., Inoue, T., & Sorano, S. (2012). An update on purple urine bag syndrome. *International journal of general medicine*, 5, 707.
- Kalsi, D. S., Ward, J., Lee, R., & Handa, A. (2017). Purple urine bag syndrome: a rare spot diagnosis. *Disease markers*, 2017.
- Khalid, L., Ali, I., Wahid, K., Khan, A. U., & Fawad, S. (2016). Purple urine bag syndrome. *J Coll Physicians Surg Pak*, 26, 863-864.
- Khan, F., Chaudhry, M. A., Qureshi, N., & Cowley, B. (2011). Purple urine bag syndrome: an alarming hue? A brief review of the literature. *International Journal of Nephrology*, 2011.
- Lin, H.-H., Li, S.-J., Su, K.-B., & Wu, L.-S. (2002). Purple urine bag syndrome: a case report and review of the literature. *J Intern Med Taiwan*, 13(13), 209-212.
- Pillai, B., Chong, V., & Yong, A. (2009). Purple urine bag syndrome. *Singapore Med J*, 50(5), e193-194.
- Rawal, G., Garg, N., Yadav, S., Wani, U., & Shokeen, P. (2015). Purple urine bag syndrome: An alarming and rare phenomenon of urinary tract infection. *Int J Med Res Rev*, 3(1), 231-233.
- Shiao, C. C., Weng, C. Y., Chuang, J. C., Huang, M. S., & Chen, Z. Y. (2008). Purple urine bag syndrome: A

community - based study and literature review. *Nephrology*, 13(7), 554-559.

Yadav, S., Rawal, G., & Singh, A. (2016). Purple urine bag syndrome: are we aware? *Journal of Integrative Nephrology and Andrology*, 3(4), 133.

Yang, H. W., & Su, Y. J. (2018). Trends in the epidemiology of purple urine bag syndrome: a systematic review. *Biomedical reports*, 8(3), 249-256.

Yaqub, S., Mohkum, S., & Mukhtar, K. (2013). Purple urine bag syndrome: A case report and review of literature. *Indian Journal of Nephrology*, 23(2), 140.

متلازمة كيس البول الأرجواني: حالة غير شائعة مرتبطة مع التهاب شائع الحدوث

مفتاح حمد الخفيفي

قسم جراحه المسالك البولية، مركز الهواري للجراحات التخصصية، بنغازي-ليبيا

تاريخ الاستلام: 21 سبتمبر 2020 / تاريخ القبول: 18 ديسمبر 2020

<https://doi.org/10.54172/mjsc.v35i3.250>:Doi

المستخلص: متلازمة كيس البول الأرجواني متلازمة طبية نادرة، لكن سُجل حدوثها أكثر في النساء المقدمات، والمتقدّمات في السن، واللاتي يشكين من الإمساك المزمن مع وجود قسرة بولية مزمنة في وجود التهابات بالمسالك البولية. المسبب الرئيسي للمتلازمة عبارة عن الالتهابات ببكتيريا معينة، تقوم بإنتاج الأنزيمات التي تؤدي إلى عملية أيض واستقلاب الحمض الأميني المعروف باسم التربتوفان حيث ينتج عدد اثنين من الصبغات التي تلون البول باللون الأرجواني. توجد عدة عوامل خطورة مرتبطة مع هذه المتلازمة ومن أهمها: الجنس الأنثوي، زيادة التربتوفان في الطعام، قلوية البول، الإمساك، القسرة البولية المقيمة لفترة طويلة، وفرة البكتيريا المسببة، الفشل الكلوي، واستعمال القسرة البولية المصنوعة من كلوريد البوليفينيل. نقدم هذه الحالة النادرة لسيدة بالغة من العمر 78 عاما، تمت معالجتها بالمضاد الحيوي، وذلك حسب تقرير زراعة البول، وتغيير القسرة البولية، وكيس تجميع البول. تم اختفاء اللون الأرجواني بالكامل بعد أسبوع من العلاج بالمضاد الحيوي وتغيير القسرة البولية وكيس تجميع البول.

الكلمات المفتاحية: التهابات المسالك البولية، القسرة البولية، البول القلوي، الحمض الأميني التربتوفان، اللون الأرجواني، بنغازي.