



Evaluation of Efficacy of Collagen-Calcium Alginate Protectants on Chronic Wound Healing in Horses

Khaled. M. A. Hussin^{1*}, Asma Saleh W², Rehab Hamad¹ and Marwan Saleh³

¹Department of Clinical Veterinary Medical Sciences, Faculty of Veterinary Medicine, Omar Al-Mukhtar University, Al-Bayda, Libya

²Department of Botany, Faculty of Science, Toubrk University, Toubrk, Libya

³Agricultural Research Center, Al-Bayda, Libya

Received: 27 December 2020/ Accepted: 15 June 2021

Doi: <https://doi.org/10.54172/mjsc.v36i2.56>

Abstract: This study aimed to evaluate the efficacy of collagen-calcium alginate as an accelerator of wound healing in a clinical case of ten horses attended at the University Veterinary Hospital (UVH) at Omar Al-Mukhtar University, having non-healing chronic wounds. The pattern of wound healing was evaluated both clinically and by planimetry. All cases showed healing progress after the application of the collagen-calcium alginate film. The study results suggested that collagen-calcium alginate film can be a better wound healing biomaterial in horses. It can be used as a less expensive skin substitute in order to stimulate and promote wound healing in animals especially in the case of chronic non-healing wounds.

Keywords: Biomaterial, Collagen-Calcium Alginate, Wound Healing, Chronic Wound.

INTRODUCTION

One of the most complicated biological events after birth is wound healing (Gopinath *et al.*, 2004; Schäffer *et al.*, 2004). It is a complex process of replacing dead tissue with vital tissue (Khaled & Ashraf, 2008; Khaled *et al.*, 2014). The aims of any wound treatment are to alleviate animal pain and discomfort, functional and cosmetic recovery, economical and time-efficient procedures, and prompt decision-making in case of signs of delayed healing. (Ashraf & Khaled, 2008; Ballard & Baxter, 2000). In chronic wounds, the main focus of wound healing has been on the relationship between tissue degradation by excess inflammation and tissue synthesis induced by a pro-healing environment. Due to their biocompatibility, biodegradability, and nontoxicity, natural polymers have been increasingly studied for health care applications (Mali *et al.*, 2006). The collagen based film is a potentially useful biomaterial since it is the main

component of the connective tissue and enables the release of regulated drugs within the target tissues (Gopinath *et al.*, 2004). Alginates are highly absorbent gel-forming materials with haemostatic properties (Blaine, 1947), and it has long been recognized that when a gel is produced on the wound surface dehydration is prevented, and rapid wound healing occurs (Winter, 1962). Alginates are known to break down to simple monosaccharide type residues in contact with body fluids and be fully absorbed. The wound exudates turn the calcium into sodium salt, allowing the dressing to dissolve by dissolution. Any remaining residual fibers inside the wound are biodegraded, thereby eliminating the need for full removal (Burrow *et al.*, 1983). With collagen-calcium alginate biomaterial, early wound healing can be encouraged (Khaled *et al.*, 2014). The present research was carried out to test the efficacy of calcium alginate film for wound healing.

*Corresponding Author: ¹Khaled. M. A. Hussin Khaled.elhmri@omu.edu.ly, Department of Clinical Veterinary Medical Sciences, Faculty of Veterinary Medicine, Omar Al-Mukhtar University, Al-Bayda.

MATERIALS AND METHODS

In the Central Leather Research Institute, Chennai, calcium alginate film was developed at a thickness of 0.2 mm (Figure1) (Khaled *et al.*, 2016; Khaled *et al.*, 2014; Rafi *et al.*, 2008). Ten horses suffering from unhealed wounds that attended the University Veterinary Hospital (UVH), Omar Al-Mokhtar University, were chosen. Wound characterizations for all horses are given in Table 1. Animals were treated with regular saline and povidone-iodine with a course of antibiotics for a period of 26 days without signs of wound healing. Wounds were treated for one to two minutes with calci-

um alginate film soaked in Gentamicin solution (Dutch Farm Veterinary Pharmaceuticals, the Netherlands).

The treatment was conducted once every three days, and four to five applications were administered to treat the wounds. Clinical observations, bacteriological analysis, and wound planimetry were determined for wound healing by square counting procedures (Richard *et al.*, 2000) at the boundary between the normal skin, the wound and the outlined region. As defined by Bohling *et al.* (2004), the percentage of epithelialization, wound contraction, and total wound healing were determined.




Figure: (1). Appearance of collagen-calcium alginate film (2 x 2cm sheet).

Table: (1). Characterization of the wounds in examined horses

Case No	Age in Months	Sex	Nature and site of wound	Exudate	Wound Size (cm ²)	Duration of Illness (days)
1	22	F	Right hand	Purulent	12.6	20
2	36	F	Left hand	Serosanguinous	7.3	11
3	53	M	Left elders from the neck	Exudates	14.3	7
4	18	F	Left hand	Exudates	16	12
5	29	F	Right elders from the neck	No exudate	8.2	7
6	48	M	Left man	Purulent	4.8	24
7	66	F	Left hand	Serosanguinous	17.8	18
8	40	F	Right hand	No exudate	9.8	26
9	33	F	Left hand	No exudate	11.6	20
10	50	M	Right hand	Serosanguinous	8.1	9

M= Male, F= Female

RESULTS

Collagen-calcium alginate film with therapeutic ultrasound massage was well tolerated in all the cases. No animals showed any intolerance or bandage disturbance throughout the treatment. The formation of healthy granulation tissue was observed in all cases without any side effects. After the first application of collagen-calcium alginate film, there was a marked reduction in wound discharge and the development of new shiny and bright red granulation tissue, which indicated angiogenesis and the healing of the wound. *Staphylo-*

coccus aureus Pseudomonas, and *Klebsiella species* were isolated from cases 1 and 7 and *Pseudomonas* from cases 5 and 6. No organisms were isolated from cases 2, 3, 4, and 8. *Staphylococcus aureus*, *Pseudomonas*, and *Klebsiella species* were the common organisms isolated from infected wounds. Wound planimetry indicated that all the cases showed progress in epithelialization, contraction, and wound healing. Contraction ceased when the epithelialization of the wound is completed (Table 2 and Figure 2).

Table: (2). Wound planimetry

Case No	Characteristics	Wound healing (%)				
		1 st (day 3)	2 nd (day 6)	3 rd (day 9)	4 th (day 12)	5 th (day 15)
1	Epithelialization	9.32	24.12	45.15	83.54	
	Contraction	13.98	32.78	73.89	89.38	NR
	Wound healing	23.09	51.12	89.43	90.58	
2	Epithelialization	11.67	32.10	56.41	89.32	
	Contraction	22.10	41.90	82.10	90.53	NR
	Wound healing	34.78	49.67	76.28	79.97	
3	Epithelialization	14.82	36.91	60.21	82.51	
	Contraction	24.18	51.88	90.16	96.32	NR
	Wound healing	22.81	46.09	88.01	82.39	
4	Epithelialization	9.89	47.32	65.28	83.05	96.21
	Contraction	32.98	63.11	82.84	93.82	94.01
	Wound healing	39.85	39.09	79.89	79.98	89.19
5	Epithelialization	18.09	31.98	67.95	83.27	89.65
	Contraction	28.97	73.52	73.92	85.36	90.27
	Wound healing	27.11	42.45	79.43	92.52	93.78
6	Epithelialization	11.98	46.98	63.63	79.54	
	Contraction	21.98	53.97	69.34	82.98	NR
	Wound healing	34.50	39.48	78.43	85.29	
7	Epithelialization	19.46	31.89	61.86	80.12	89.84
	Contraction	34.98	58.65	79.49	89.63	92.87
	Wound healing	25.98	41.96	81.95	79.54	86.37
8	Epithelialization	13.87	42.97	63.94	79.73	
	Contraction	27.52	63.52	75.89	88.89	NR
	Wound healing	29.89	52.90	79.85	84.95	
9	Epithelialization	10.86	35.89	59.12	78.23	87.97
	Contraction	35.89	61.90	81.13	91.99	96.78
	Wound healing	32.97	41.97	72.89	82.12	92.98
10	Epithelialization	11.98	38.96	60.87	75.89	
	Contraction	33.87	58.93	78.93	92.98	NR
	Wound healing	39.53	60.19	80.31	90.23	

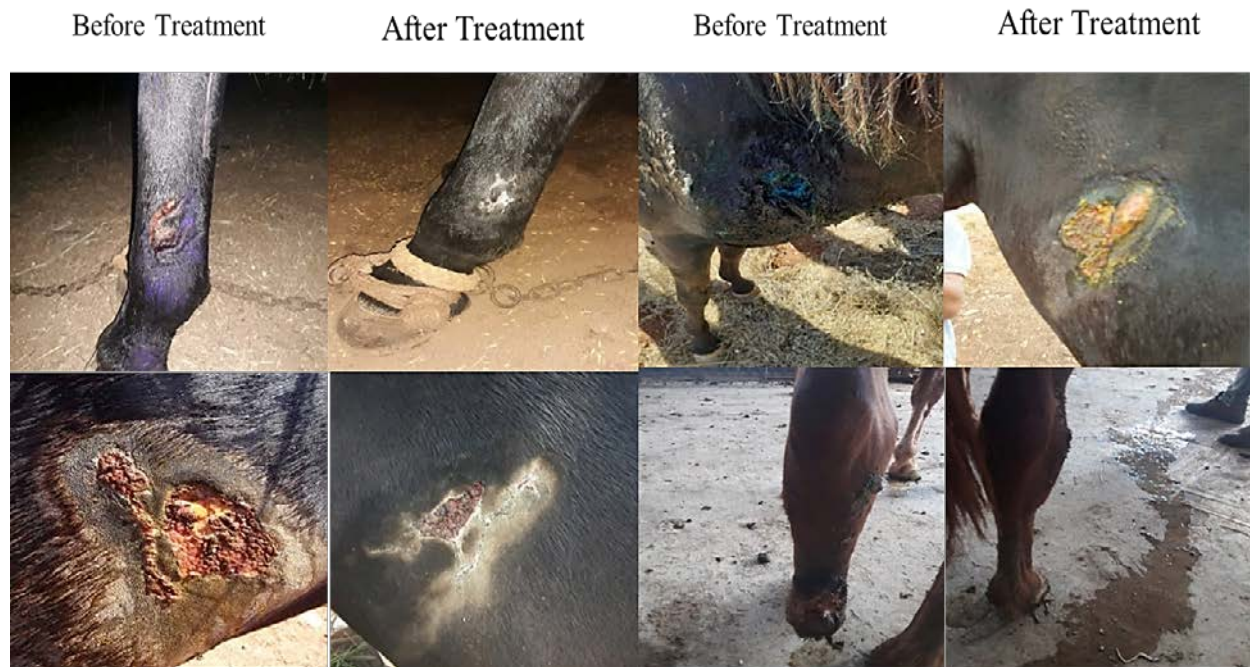

Figure: (2) Wound characterization and healing percentages for fifteen days

DISCUSSION

In all cases, the application of collagen-calcium alginate film was well tolerated by the animals. The collagen-calcium alginate film is easy to apply on the wound without any adverse reaction and was well accepted by all the animals. The application of collagen-calcium alginate film did not show any adhesion of the gauze during wound dressing.

The colour of the wound bed in all cases was red while cases 2 and 5 showed a bright beefy red colour, which indicates healthy granulation tissue with neovascularisation (Taylor & Bayat, 2003), and resistance to infection until the epithelial barrier is re-established (Hosgood, 2003; Pope, 1993). The bright red colour observed is due to the microvascular network throughout the granulation tissue (Tonnesen *et al.*, 2000). The basic fibroblast growth factor sets the stage for angiogenesis during the first three days of wound repair (Schäffer *et al.*, 2004) and plays an important role in granulation tissue formation and the wound healing process (Takehara, 2000). Granulation in all the cases

was flat without any exuberant nature; granulation tissue with a smooth surface facilitates the migration of epithelial cells (Pope, 1993). In cases 1,3,4,6,7,8,9, and 10 the granulation tissue was red in colour due to neovascularisation (Taylor & Bayat, 2003). Mal-odour was observed up to Day 12 in all cases (Taylor & Bayat, 2003). The presence of bacterial infection was the common cause for the mal-odour observed, because all the wounds were infected. Serous discharge was noticed up to Day 12 in cases 2 and 5, and mild serous discharge was noticed up to Day 8 in cases 4 and 9; subsequently, the discharge was reduced because healthy vascular granulation tissue is resistant to infection (Hosgood, 2003; Pope, 1993). On Day 4, epithelialisation was significantly better in all cases, because collagen from the wound margins began to migrate to form new epithelium (Rangaraj *et al.*, 2011).

The percentage of wound contraction on post wound Days 4 and 8 of all cases showed no significant difference, this may be because of an inherent property of fibroblasts that appears early in the process of wound contraction after

some time, do not contract as forcefully as those that appear later (Bohling *et al.*, 2004). All the cases showed a maximum mean percentage of total wound healing from Days 4 to 8; this is in concurrence with the results of Bohling *et al.* (2004) but differs from the findings of (Swaim *et al.*, 1993). *Staphylococcus aureus*, *Pseudomonas*, *Klebsiella* *Escherichia coli* is the common infection in wounds (Kumar *et al.*, 2006). All wounds can be contaminated regardless of the precautions taken (Arul Jothi *et al.*, 2006). Collagen-calcium alginate film is a biocompatible protein that does not interfere with the body's normal immunologic response and can be used in non-healing chronic wounds, which require a trigger to stimulate the normal healing process.

CONCLUSION

The present study has shown that collagen-calcium alginate film can be used as a wound-healing stimulant to promote the healing of chronic wounds in animals. This is a promising finding because collagen-calcium alginate film is an inexpensive biomaterial as a skin substitute to stimulate wound healing in animals where the cost of treatment is a major consideration.

ACKNOWLEDGEMENT

The authors would like to thank the University Veterinary Hospital (UVH), Omar Al-Mukhtar University, Al-Bayda, Libya for the facilities provided and help rendered during the study.

REFERENCES

Arul Jothi, N., Thilagar, S., Khaled, M., Thevi, S. G., Lau, S., & Sastry, T. (2006). Clinical evaluation of keratin-gelatin composite film for wound healing in cats. *Indian Journal of Veterinary Surgery*, 27(2), 108-110.

Ashraf, A.-h. H., & Khaled, M. A. (2008). Diagnosis of joint affection in camels by studies on synovial fluid which give the degree of affections & response to

treatment. *Al-Mukhtar Journal of Sciences*, 20(1), 58-72.

- Ballard, K., & Baxter, H. (2000). Developments in wound care for difficult to manage wounds. *British Journal of Nursing*, 9(7), 405-412.
- Blaine, G. (1947). Experimental observations on absorbable alginate products in surgery: gel, film, gauze and foam. *Annals of surgery*, 125(1), 102-114.
- Bohling, M. W., Henderson, R. A., Swaim, S. F., Kincaid, S. A., & Wright, J. C. (2004). Cutaneous wound healing in the cat: a macroscopic description and comparison with cutaneous wound healing in the dog. *Veterinary Surgery*, 33(6), 579-587.
- Burrow, T., Welch, M., & Cusick, G. (1983). The development and use of alginate fibres in nonwovens for medical end-uses. *Nonwoven Conference Papers*, UMIST: 49-68.,
- Gopinath, D., Ahmed, M. R., Gomathi, K., Chitra, K., Sehgal, P., & Jayakumar, R. (2004). Dermal wound healing processes with curcumin incorporated collagen films. *Biomaterials*, 25(10), 1911-1917.
- Hosgood, G. (2003). *Wound repair and specific tissue response to injury, Textbook of small animal surgery. 3rd ed Philadelphia: WB Saunders (Vol., 327-329).*
- Khaled, M. A., & Ashraf, A. (2008). Unusual foreign bodies cause obstruction of the esophagus in dogs. *Al-Mukhtar Journal of Sciences*, 19(1), 51-61.
- Khaled, M. A., Asma, S., Almahdi, A., & Kalthum, H. (2016). Clinical Evaluation of Collagen-Calcium Alginate Film along with Therapeutic Ultrasound

- Massage for Wound Healing in Cats. *Acta Biologica Malaysiana*, 5(2&3), 49-52.
- Khaled, M. A., Asma, S., Nawara, M., A. k., & Marwan, S. W. (2018). Effects of Different Types of Honey on Wound Healing in rats. *Al-Mukhtar Journal of Sciences* 33(3), 211-220.
- Khaled, M. A., Jalila, A., Kalthum, H., Noordin, M., & Saleh, W. A. (2014). Collagen-Calcium Alginate Film Dressing with Therapeutic Ultrasound to Treat Open Wound in Rats. *Research Journal of Biological Sciences*, 9(2), 57-61.
- Kumar, M. S., Sripriya, R., Raghavan, H. V., & Sehgal, P. K. (2006). Wound healing potential of Cassia fistula on infected albino rat model. *Journal of Surgical Research*, 131(2), 283-289.
- Mali, S., Grossmann, M. V. E., García, M. A., Martino, M. N., & Zaritzky, N. E. (2006). Effects of controlled storage on thermal, mechanical and barrier properties of plasticized films from different starch sources. *Journal of food engineering*, 75(4), 453-460.
- Parker, L. (2000). Applying the principles of infection control to wound care. *British Journal of Nursing*, 9(7), 394-404.
- Pope, E. R. (1993). *Skin healing .In: Disease mechanisms in small animal surgery. 2nd ED Philadelphia, London, 152-155.*
- Rafi, M. E. A., Ashraf, A.-h. H., & Khaled, M. A. (2008). Foreign bodies in the rumen of the sheep and goats. *Al-Mukhtar Journa of Sciences*, 19(1), 38-50.
- Rangaraj, A., Harding, K., & Leaper, D. (2011). Role of collagen in wound management. *Wounds uk*, 7(2), 54-63.
- Richard, J., Daures, J., Parer-Richard, C., Vannereau, D., & Boulot, I. (2000). Of mice and wounds reproducibility and accuracy of a novel planimetry program for measuring wound area. *Wounds-A Compendium of Clinical Research and Practice*, 12(6), 148-154.
- Schäffer, M. R., Tantry, U., & Barbul, A. (2004). Wound fluid inhibits wound fibroblast nitric oxide synthesis. *Journal of Surgical Research*, 122(1), 43-48.
- Swaim, S., Bradley, D., Spano, J., McGuire, J., Hoffman, C., & Trachy, R. (1993). Evaluation of multipeptide-copper complex medications on open wound healing in dogs. *The Journal of the American Animal Hospital Association*, 29(6), 519-525.
- Takehara, K. (2000). Growth regulation of skin fibroblasts. *Journal of dermatological science*, 24, S70-S77.
- Taylor, B., & Bayat, A. (2003). Basic plastic surgery techniques and principles: Wound healing. *Student British Medical Journal (BMJ)*, 11(2), 406-407.
- Tonnesen, M. G., Feng, X., & Clark, R. A. (2000). Angiogenesis in wound healing. *Journal of Investigative Dermatology Symposium Proceedings*, 5(1), 40-46.
- Winter, G. D. (1962). Formation of the scab and the rate of epithelization of superficial wounds in the skin of the young domestic pig. *Nature*, 193(4812), 293-294.

تقييم فعالية واقيات الكولاجين والكالسيوم أجنينات في التئام الجروح المزمنة في الخيول

خالد مسعود عبدالحق^{1*}، أسماء صالح ونيس²، رحاب لسنوسي¹ ومروان صالح³

¹ قسم العلوم الطبية البيطرية السريرية، كلية الطب البيطري، جامعة عمر المختار، البيضاء، ليبيا

² قسم النبات، كلية العلوم، جامعة طبرق، طبرق، ليبيا

³ مركز البحوث الزراعية، البيضاء، ليبيا.

تاريخ الاستلام: 27 ديسمبر 2020 / تاريخ القبول: 15 يونيو 2021

<https://doi.org/10.54172/mjsc.v36i2.56>:Doi

المستخلص : هدف الدراسة تقييم فعالية الكولاجين الكالسيوم أجنينات؛ لتسريع التئام الجروح في الخيول التي تعاني جرحاً مزمناً غير قابل للشفاء، هذه الخيول كانت موجودة في المستشفى البيطري الجامعي (UVH) جامعة عمر المختار. تم تقييم نمط التئام الجروح على المستوى الإكلينيكي. أظهرت جميع الحالات تقدماً جيداً في الشفاء بعد دهن غشاء الكولاجين الكالسيوم أجنينات. اقترحت نتائج الدراسة أن فيلم الكالسيوم الكولاجين أجنينات يمكن أن يكون مادة حيوية أفضل في التئام الجروح في الخيول، ويمكن استخدامه بديلاً جديداً أقل تكلفة لتحفيز التئام الجروح المزمنة التي لا تلتئم في الحيوانات.

الكلمات المفتاحية : المادة الحيوية ، الكولاجين الكالسيوم أجنينات ، التئام الجروح ، الجروح المزمنة.

*1 خالد مسعود عبد الخالق Khaled.elhmri@omu.edu.ly قسم العلوم الطبية البيطرية السريرية، كلية الطب البيطري، جامعة عمر المختار، البيضاء، ليبيا